

Frequency of Upper Gastrointestinal Tract Lesions as detected on Endoscopic Biopsies in patients Presenting with Iron Deficiency Anemia at a Tertiary Care Hospital in Lahore

NASIR AHMED¹, *USMAN JAVED IQBAL², HAFIZ MOEEN UD DIN³

ABSTRACT

Aim: To determine the frequency of various lesions of upper gastrointestinal tract disorders detected in patients with iron deficiency anemia upon endoscopic biopsy.

Methods: This was a cross sectional study conducted in department of Medicine of Lahore General Hospital from 25-11-2013 to 25-05-2014. All the patients with the diagnosis of iron deficiency anemia & having stool positive for occult blood were included in the study. Patients with history of previous gastric surgery and patients who refused to participate were excluded. After taking an informed consent upper GI endoscopy of all selected patients was done by consultant gastroenterologist and the biopsies were sent to laboratory for histopathological study to make the appropriate diagnosis. In addition to collecting basic demographic details all these findings were recorded on a short structured proforma. The data were analyzed using SPSS v.16.0. Qualitative data were presented in the form of %ages & graphs while mean±S.D were used for quantitative analyses.

Results: Mean age of our patients was 29.8±6.7 years. There was an overall female predominance (71.61%). Out of total 310 patients of iron deficiency anemia upper GI tract lesions were detected in 144(46.45%) while 166(53.55%) had no findings of the morbidity. With respect to frequency of various lesions of upper gastrointestinal tract 43(29.86%) had erosive gastritis, 48(33.33%) had gastric ulcer, 27(18.75%) had erosive duodenitis while 26(18.06%) had gastric malignancy as detected on endoscopic biopsy.

Conclusion: The frequency of upper GIT lesions/disorders found in our patients with iron deficiency anemia was 46.4%. The most common upper GIT lesion was gastric ulcer followed by erosive gastritis, erosive duodenitis and gastric malignancy.

Keywords: Gastrointestinal bleeding, Capsule Endoscopy, Biopsy, Iron deficiency anemia

INTRODUCTION

Iron deficiency (hypochromic microcytic) anemia is a common cause of anaemia either due to poor intake or chronic blood loss¹. Iron deficiency anemia (IDA) affects approximately 30% of the world's population². Important implications for the recognition of IDA include diagnosis and correction of underlying causes, most of which are identifiable, by means of conventional upper gastrointestinal endoscopy and colonoscopy³. In 20% of patients with IDA a routine upper and lower GI endoscopy may not ascertain GI cause during hospital admission. Previous studies^{3,4,5,6} reported upper gastrointestinal tract disorders as the main etiology of iron deficiency anemia. The notable lesions that were identified in these studies were peptic ulcer, erosive gastritis, erosive duodenitis and gastric malignancy.

¹Medical Officer, Medicine Unit, General Hospital, Lahore.

²Demonstrator, Postgraduate Medical Institute/Gulab Devi Chest Hospital.

³Assistant Prof. Anatomy, Allama Iqbal Medical College, Lahore.

*Correspondence to Dr. Usman Javed Iqbal; Email: sh.usmanjavediqbal@gmail.com

The rationale of this study is to determine the actual frequency of upper gastrointestinal tract lesions as results are markedly variable in literature and there is no comprehensive study that is conducted in our population so this study will generate baseline results.

MATERIALS & METHODS

This was a cross sectional study conducted in department of Medicine of Lahore General Hospital from 25-11-2013 to 25-05-2014. Using non probability purposive sampling a calculated sample of 310 patients (with 2.5% margin of error, 95% confidence level taking expected percentage of GIT disorder as 5.23%³) were selected on the basis of diagnosed iron deficiency anemia (as per operational definition) with symptom of easy fatigability, palpitation and shortness of breath, leg cramps, pale skin and having signs of occult blood in stool. Patients with history of previous gastric surgery, bleeding disorders and those that were on

Multivitamins like vitamin C and iron preparation 48-72 before stool for occult blood were excluded. After taking an informed consent upper GI endoscopy of all selected patients was done by consultant gastroenterologist and the biopsies were sent to laboratory for histopathological study to make the appropriate diagnosis. In addition to collecting basic demographic details all these findings were recorded on a short structured proforma. The data were entered and analyzed using SPSS v.16.0. Qualitative data were presented in the form of % ages & graphs while mean±S.D was used for quantitative analyses.

RESULTS

Mean age of our patients was 29.8±6.7 years. Out of total 310 patients 187 (60.3%) were between 20-30 years of age and 123 (39.6%) were in the range of 31-45 years. There was an overall female predominance (71.6%). 28.3% (88) of our patients were male and 71.6% (222) were females.

Table 1: Basic demographic profile

Age in years (mean±SD)	29.8±6.7
20-30 years	187(60.3%)
31-45 years	123(39.6%)
Male	88(28.4%)
Female	222(71.6%)

The frequency of upper gastrointestinal tract lesions (in terms of any GIT abnormality present or absent as evaluated by biopsy) detected in our patients with iron deficiency anemia is shown in Fig 1.

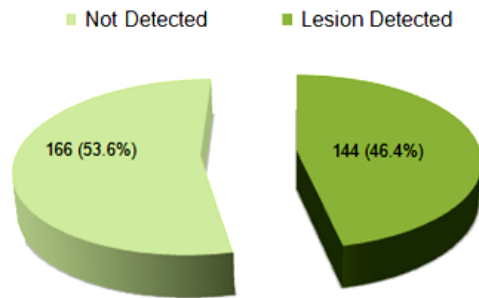


FIG-01: FREQUENCY OF UPPER GIT LESIONS IN OUR PATIENTS WITH IRON DEFICIENCY ANEMIA

Out of total 310 patients of iron deficiency anemia 144 (46.4%) patients were having GIT lesion as a morbidity and 166 (53.6%) were having no morbidity.

Fig. 2 shows frequency of various upper gastrointestinal tract lesions detected in patients with iron deficiency anemia. Out of 144 cases 43(30%) of the patients had erosive gastritis, 48(33%) had gastric ulcer, 27(19%) had erosive duodenitis while 26(18%) had gastric malignancy.

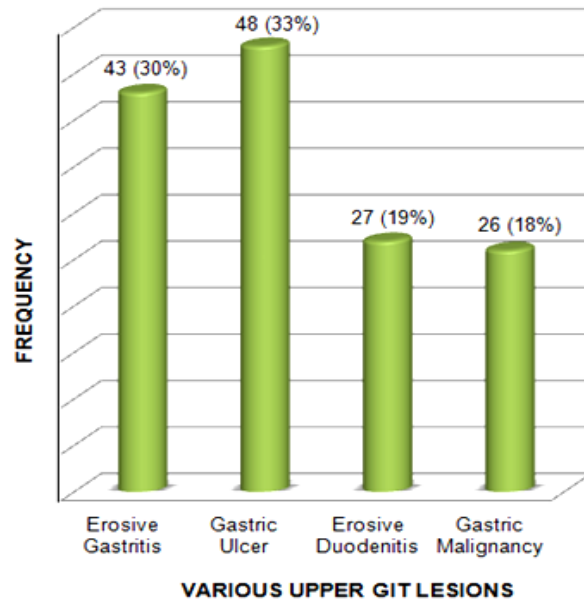


FIG-02: FREQUENCY OF VARIOUS UPPER GIT LESIONS IN OUR PATIENTS

DISCUSSION

Iron deficiency and ultimately IDA develops when there is a mismatch between iron inputs and outputs. In many cases, these alterations will be secondary to gastrointestinal disease⁷. In addition to investigate the signs and symptoms to make an appropriate diagnosis gastrointestinal endoscopy might be performed which is highly sensitive and specific for locating gastrointestinal lesions that produce anemia^{8,9}.

This paper is an attempt to find the frequency of various upper gastrointestinal lesions (upon endoscopy) as they are present in patients presenting with iron deficiency anemia in our local community.

The results of our study are comparable to literature previously reported. Fireman Z et al⁵ reported the upper gastrointestinal lesions in 55.8% of their patients on endoscopic evaluation of Iron deficiency anemia. They reported erosive gastritis in 27.9% and erosive duodenitis in 9.3% as the notable morbidities as that of detected in our study too but the frequency of these morbidities are slightly higher in our study. Such unexplained dynamic distribution of the morbidities in our study is not clearly understood.

In another study conducted by Gordon SR et al⁴ upper gastrointestinal source of iron deficiency anemia was identified in 41% patients. These findings are comparable to that of our results as 46.4% of our patients with iron deficiency anemia

have been reported of having upper gastrointestinal lesion as detected on endoscopy.

Similarly Annibale et al¹⁰ found GI causes of the iron deficiency anemia in 85% of cases. This variation of frequency as compared to our study might be due to the fact that major portion of their patients were belonged to old age group while we included patients in the range of 20-45 years only.

A study conducted in Iran¹¹ found these lesions in 34% of iron deficient patients and approximately 10% were diagnosed with gastrointestinal malignancy as a cause for their anemia and in 66% of the patients had no gastrointestinal cause was recorded. In our study Out of total 310 patients of iron deficiency anemia 144(46.4%) patients were having GIT lesion as a morbidity and 166(53.6%) were having no morbidity. Out of 144 cases 43(30%) of the patients had erosive gastritis, 48(33%) had gastric ulcer, 27(19%) had erosive duodenitis while 26(18%) had gastric malignancy. The findings of our study are in agreement with the above studies; however, these findings are primary in our study as there is no comprehensive study that was conducted in our population so this study generated baseline results. Some other trials are required to authenticate the findings of our study.

CONCLUSION

The frequency of upper GIT lesions/disorders found in our patients with iron deficiency anemia was 46.4%. The most common upper GIT lesion was gastric ulcer followed by erosive gastritis, erosive duodenitis and gastric malignancy.

REFERENCES

1. Ucarda D, Gulter S, Cenel O, Yakarilmaz F, Atasoy P, Çalyan O. Celiac disease prevalence in patients with iron deficiency anemia of obscure origin. *Turk J Gastroenterol* 2009;20:266-270
2. Zamani F, Mohamadnejad M, Shakeri R. Gluten sensitive enteropathy in patients with iron deficiency anemia of unknown origin. *World Journal of Gastroenterology* 2008;14:7381-5.
3. Shahid Majid, Mohammad Salih, Rozina Wasaya and Wasim Jafri. Predictors of gastrointestinal lesions on endoscopy in iron deficiency anemia without gastrointestinal symptoms. *BMC Gastroenterology* 2008;8:52
4. Gordon SR, Smith RE, Power GC. The role of endoscopy in the evaluation of iron deficiency anemia in patients over the age of 50. *Am J Gastroenterol.* 1994 Nov;89(11):1963-7.
5. Fireman Z, Zachlka R, Mouch SA, Kopelman Y. The Role of Endoscopy in the Evaluation of Iron Deficiency Anemia in Premenopausal Women. *IMAJ* 2006;8:88-90
6. Sajid MU, Saeed F, Ashraf HM. The Diagnostic Yield Of Upper Gastrointestinal Endoscopy In Patients With Iron Deficiency Anaemia. *PAFMJ*;4(12).
7. Bermejo F, García-López S. A guide to diagnosis of iron deficiency and iron deficiency anemia in digestive diseases. *World journal of gastroenterology: WJG.* 2009;15(37):4638
8. Sawhney MS, Lipato T, Nelson DB, Lederle FA, Rector TS, Bond JH, et al. Should patients with anemia and low normal or normal serum ferritin undergo colonoscopy? *Am J Gastroenterol.* 2007;102:82-88.
9. Hardwick RH, Armstrong CP. Synchronous upper and lower gastrointestinal endoscopy is an effective method of investigating iron-deficiency anaemia. *Br J Surg.* 1997;84:1725-28.
10. Annibale B, Capurso G, Chistolini A, D'Ambra G, DiGiulio E, Monarca B, Dellefave G. Gastrointestinal causes of refractory iron deficiency anemia in patients without gastrointestinal symptoms. *The Am J Med* 2001;111:439-45.
11. Patterson RN, Johnston SD. Iron deficiency anemia: are the British Society of Gastroenterology guidelines being adhered to? *Postgraduate Medical Journal.*2003;79:226.